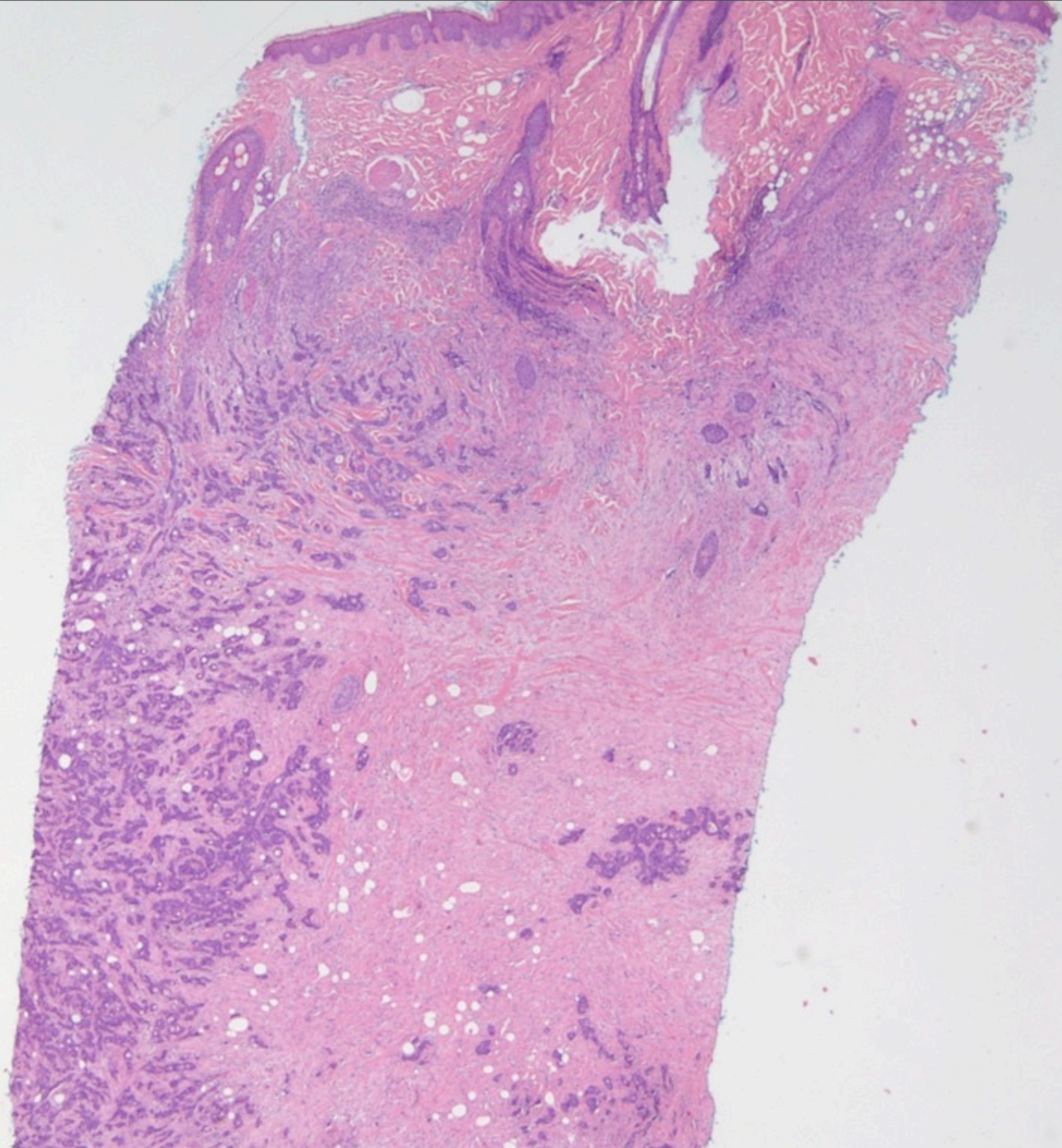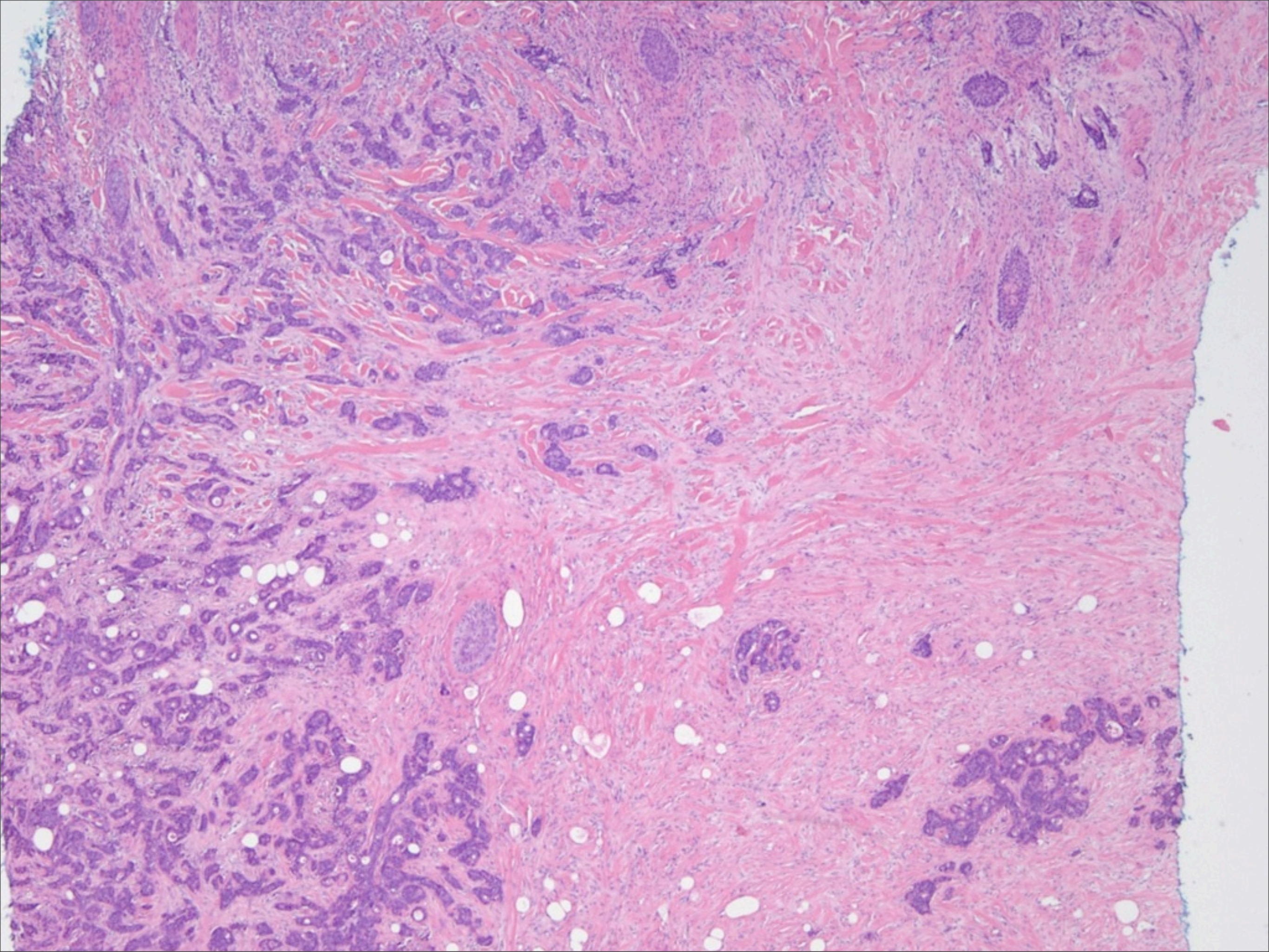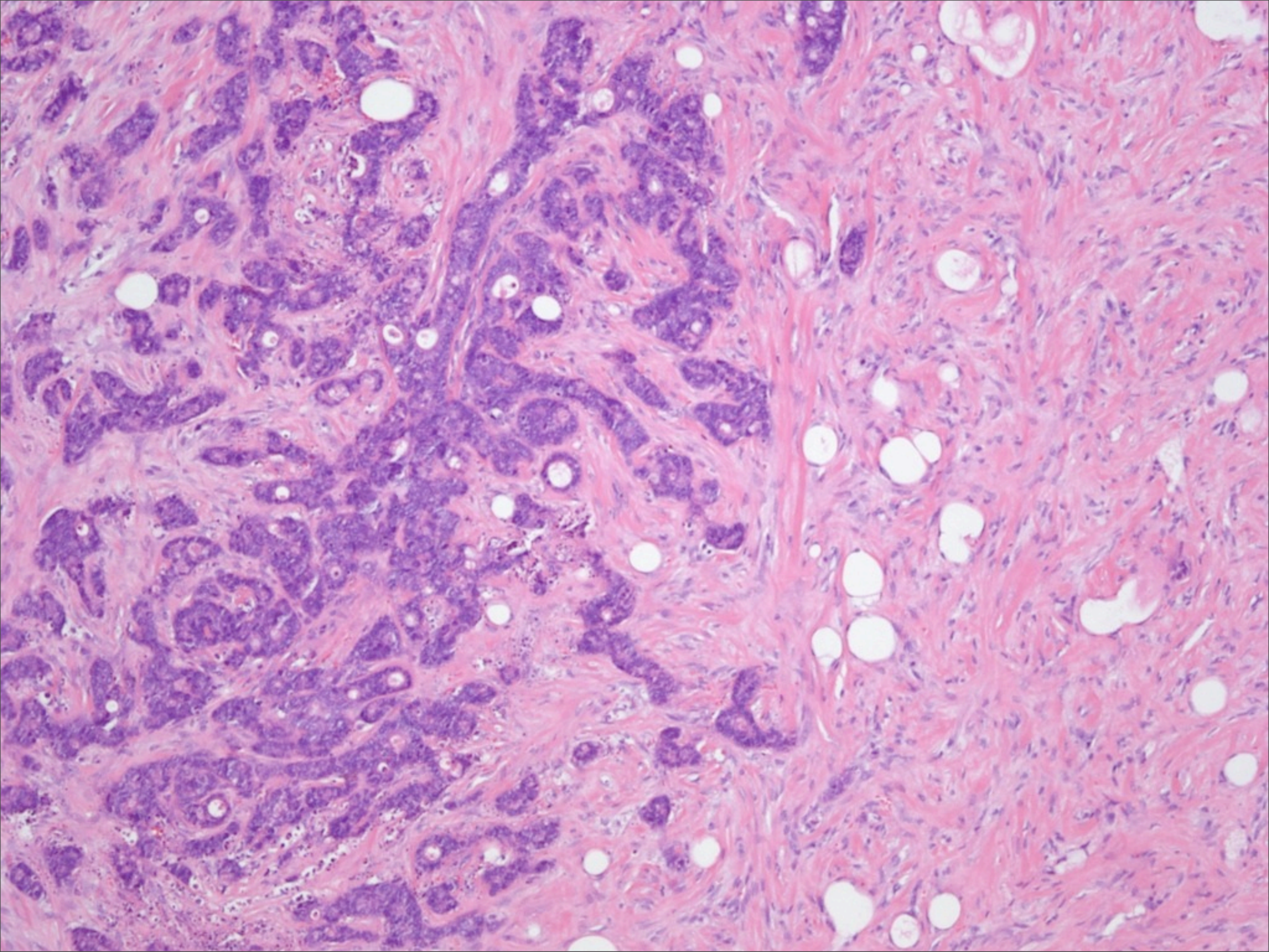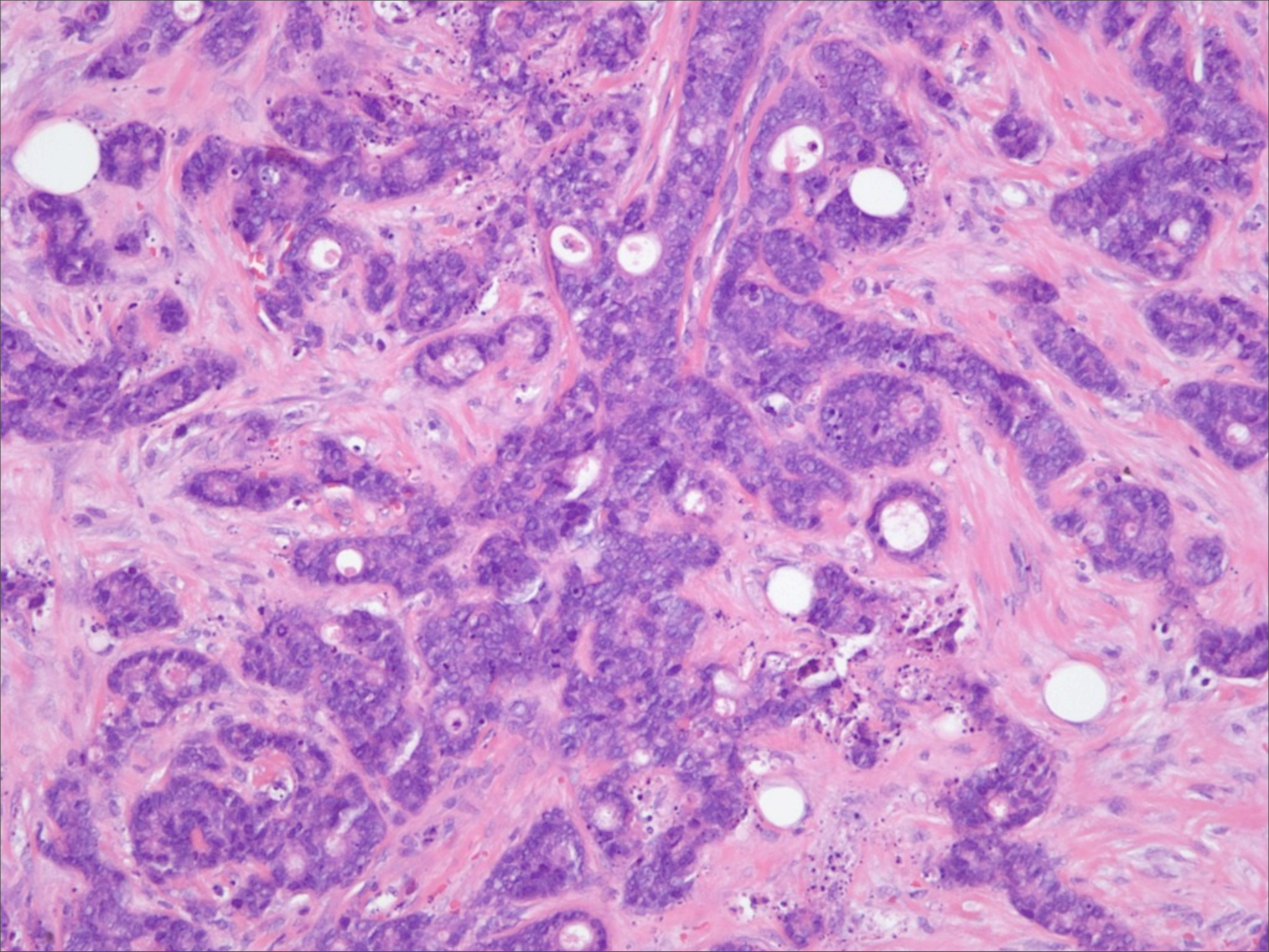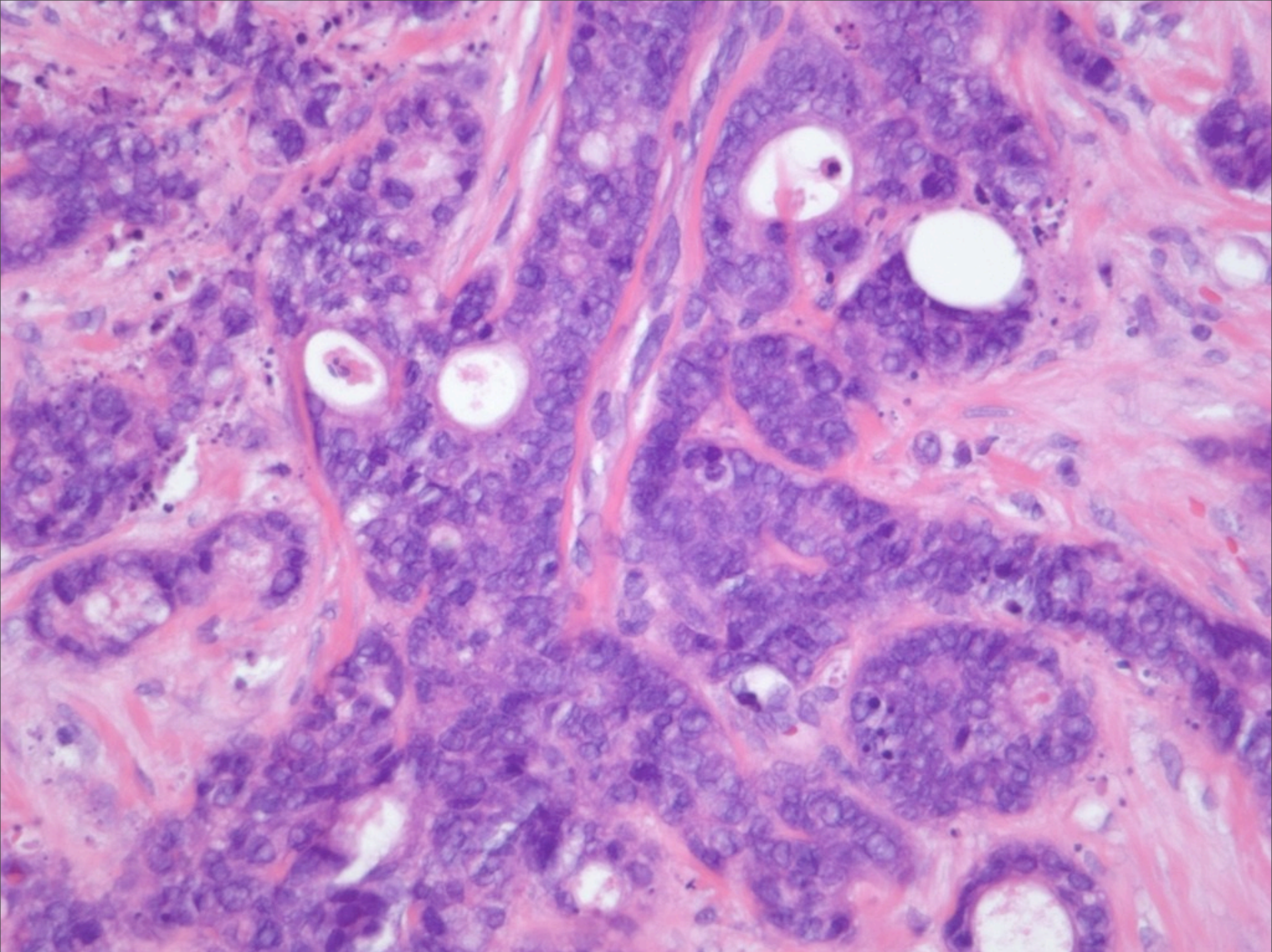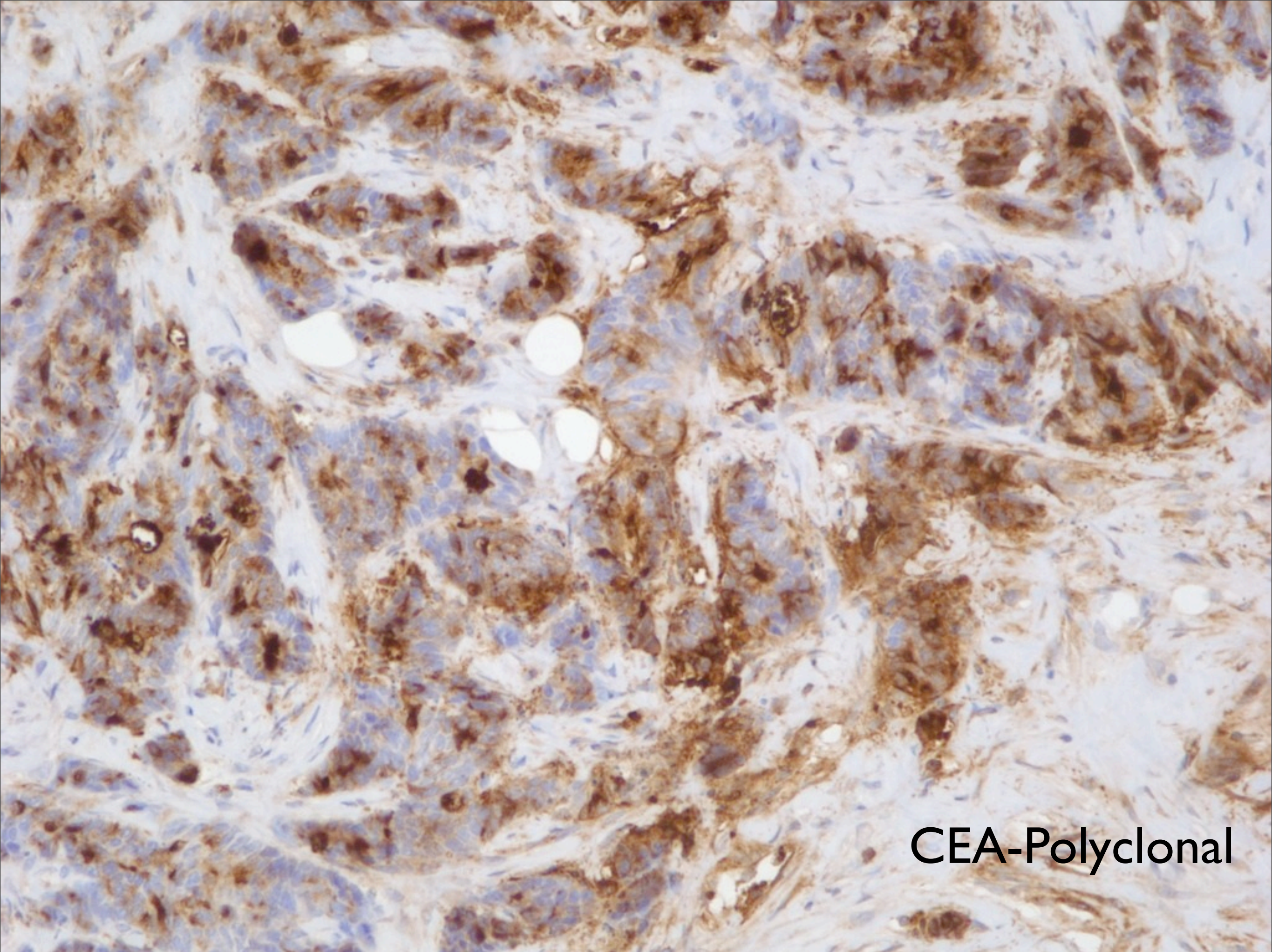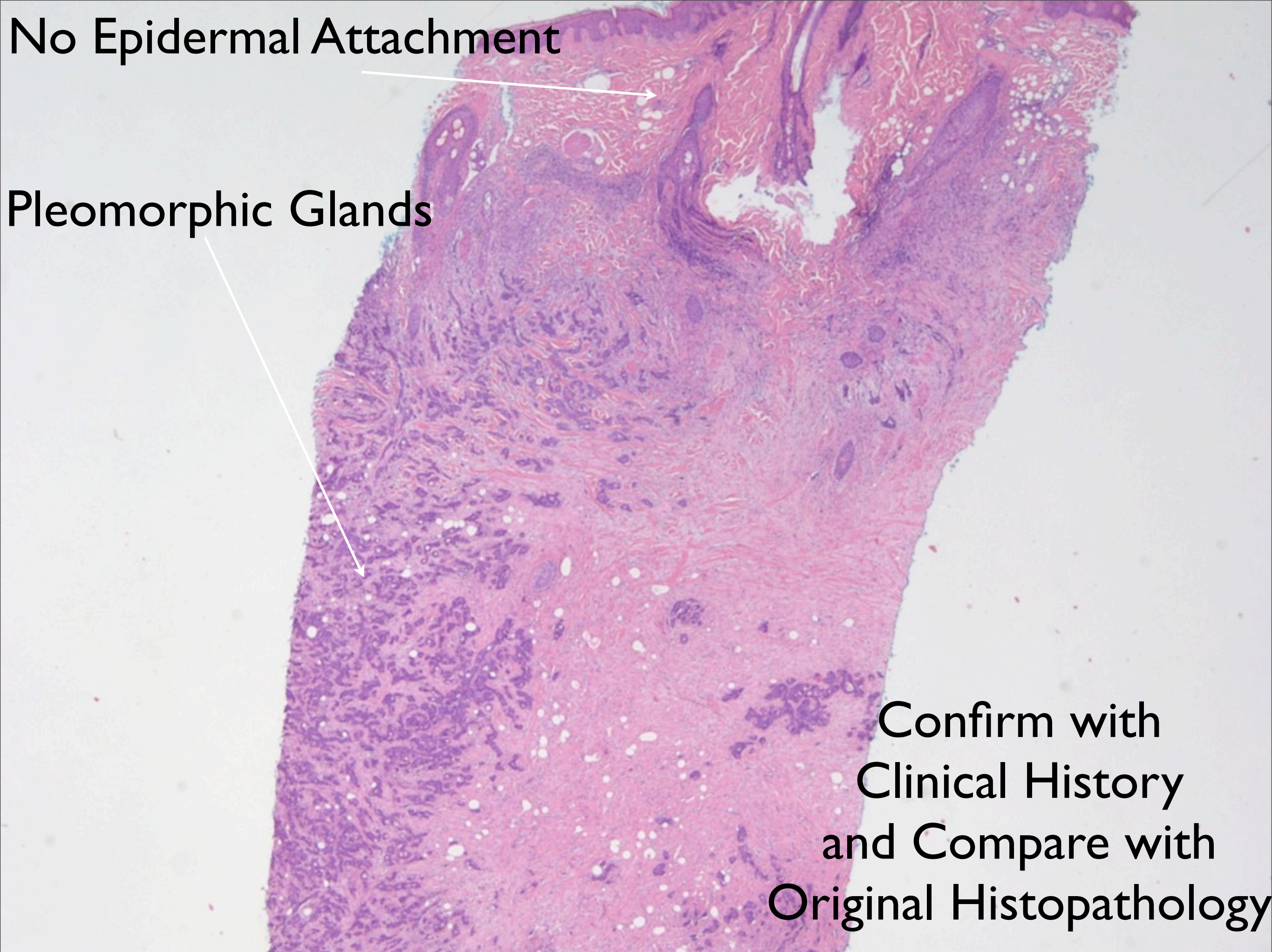


CEA-Polyclonal



# Metastatic Adenocarcinoma to the Skin, Consistent with Esophageal Primary





No Epidermal Attachment

Pleomorphic Glands

Confirm with  
Clinical History  
and Compare with  
Original Histopathology